REVIEW ARTICLE

Braz J Cardiovasc Surg 2005; 20(2): 167-173

Surgical treatment of atrial fibrilation

Tratamento cirúrgico da fibrilação atrial

Carlos Alberto Cordeiro de ABREU FILHO[1], Luiz Augusto Ferreira LISBOA[1], Luís Alberto Oliveira DALLAN[1], Sérgio Almeida de OLIVEIRA[1]

RBCCV 44205-748

INTRODUCTION

Atrial fibrillation (AF) is a sustained tachyarrhythmia commonly seen in the clinical practice. It can present with high morbid-mortality rates due to hemodynamic involvement, the cardiomyopathy originating from the tachycardia and to the occurrence of thromboembolic phenomena [1].

The association between AF and structural heart diseases is common among patients with mitral valve disease indicated for surgery, with from 40% to 60% of the cases presenting with AF during the surgery [2].

It is fundamental that the electrophysiological bases of this arrhythmia are well understood to comprehend its symptoms and to establish the correct treatment. James Cox [3] proposed a new classification of the symptoms of the disease. The classification is based on the constancy of arrhythmia or not. Thus, AF can appear in two principal

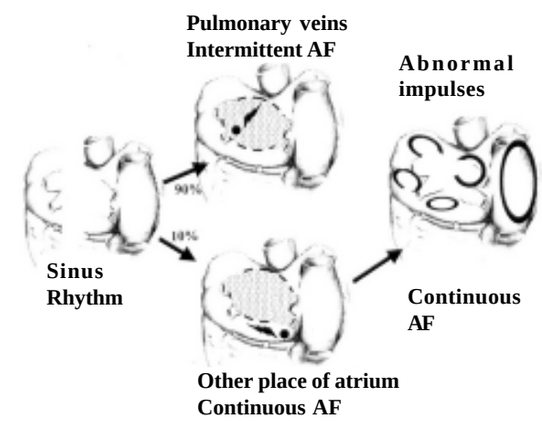

Fig. 1 – Electrophysiologic bases of the two main clinical forms of atrial fibrillation AF), paroxysmal (intermittent) and Permanent (continuous) adapted from Cox3

Work performed in the Instituto do Coração – Incor/ FMUSP – São Paulo, SP.

Correspondence address: Carlos Alberto Cordeiro Abreu Filho. Av. Dr. Enéas de Carvalho Aguiar, 44. 2°andar. Cerqueira César. São Paulo, SP. CEP: 05403-001. Tel: (11) 3069-5014. E-mail: carlos.filho@incor.usp.br

Article received in February, 2005
Article accepted in June, 2005

clinical forms, intermittent and continuous, constituted by different electrophysiological bases. Figure 1 shows the electrophysiological bases of the two main clinical forms of AF.

According to the American College of Cardiology/ American Heart Association classification [4], the intermittent form corresponds to the paroxysmal and persistent forms, while the continuous form would be equivalent to the permanent form of AF.

Surgical treatment of AF is normally recommended in cases of permanent AF with associated structural heart diseases with surgical indication. The main aims of the surgical treatment of permanent AF are: to relieve the propitiated symptoms by reestablishing sinus rhythm, atrioventricular resynchronization, to maintain the effective atrial contractility, with a consequent improvement in the hemodynamic performance and to reduce the risk of thromboembolic phenomena occurring [5].

The surgical procedure able to fulfill these objectives was described as the Maze technique, presented by James L. Cox et al. [6] in 1991. The "Cox-Maze" surgery consists in performing multiple incisions and atrial sutures with the purpose of blocking abnormal electrical impulses, involved in the synthesis and maintenance of AF, as well as allowing electric impulses to homogeneously activate all the atrial myocardium.

After two technical alterations, the authors arrived at the "Cox-Maze" III surgery [7], which has been used since 1992, presenting satisfactory results in terms of reestablishing the sinus rhythm, with success rates of around 98%. But in spite of its high efficacy, its utilization has not been widely spread due to the surgery's high technical complexity, demanding a long cardiopulmonary bypass time and presenting with a high risk of bleeding in the postoperative period because of the many surgical incisions.

Hence, in spite of the "Cox-Maze" III surgery being efficient and reliable (operative mortality is less than 1%) few patients with AF are submitted to the surgery. This proves the need for surgical alternatives to treat permanent AF with a lower degree of complexity, in order to provide the benefits of the surgery to a greater number of patients.

MODERN ALTERNATIVES IN THE SURGICAL TREATMENT OF ATRIAL FIBRILLATION

The evolution of AF surgery included the development of less invasive surgical techniques, through the substitution of the incisions and atrial sutures by the use of energy sources on the atrial myocardium, with the goal of creating transmural lesions which block abnormal electric impulses. The main energy sources employed currently include cryothermia, radiofrequency, microwaves, ultrasound and laser.

The systems available for ablation consist of an energy generator and an apparatus that applies the energy to the tissues. The application apparatus allows ablation lines to be created in the endocardium or in the atrial epicardium.

The ablation lines are created sequentially similar to the incisions of the conventional "Cox-Maze" III technique, but the concept of vital lesions must be remembered, that is, only the lesions considered essential should be made so as to obstruct the abnormal impulses and to revert the AF.

In the right atrium, the essential lesions involve the cavotricuspid isthmus, that is, the lesion performed along the lower edge of the tricuspid valve annulus, passing by the coronary sinus and continuing in the direction of the inferior vena cava orifice [8]. When creating this lesion, independently of the energy source utilized, it is recommended to perform an associated cryoblation of the coronary sinus ostium. Due to its thickness cryoablation is necessary to produce the transmural lesion.

In the left atrium, the essential lesions involve the isolation of the pulmonary veins, with the left veins in one block and the right veins in another and the left atrium isthmus, that is the connection between the left pulmonary veins and the mitral valve annulus.

Figure 2 shows the electrophysiological bases of surgeries for the treatment of AF, with the obstruction of abnormal impulses by incisions and sutures or by ablation using energy sources.

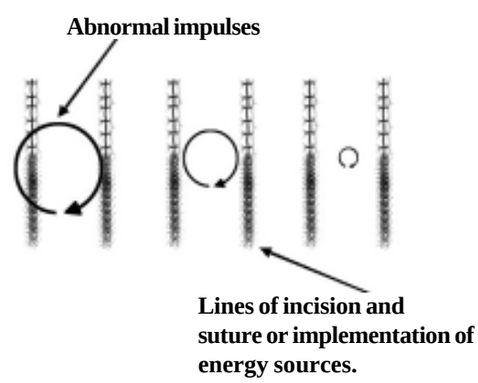

Fig. 2 – Diagram illustrating: the sectioning lines and sutures blocking the abnormal electric impulses responsible for the maintenance of atrial fibrillation

1. Cryoablation

Cryothermia was the fist energy source to be utilized to create transmural lesions in the surgical treatment of AF.

The surgery called the "Mini-Maze" surgery [9] also created by James L. Cox, involves creating only the essential lesions in the right and left atria and can be achieved by sectioning and atrial sutures associated with the utilization of cryothermia.

Cryoablation was employed by several authors giving satisfactory results in terms of the reestablishment of sinus rhythm. Sueda et al. [10] reported a success rate of 78%, Gaita et al. [11] performed cryoablation only in the left atrium in patients who underwent associated valve surgeries, obtaining a conversion rate to sinus rhythm of 70%.

2. Radiofrequency

Endocardial ablation

There are several studies about the endocardial radiofrequency ablation technique. Gillinov et al. [1], in a review article, considered radiofrequency ablation to be an efficient technique in the treatment of permanent AF in patients with associated heart diseases. According to these authors, the success rate of reestablishing sinus rhythm varies from 70% to 80%.

Sie et al. [12] accompanied patients who were submitted to mitral valve surgeries associated with surgical radiofrequency ablation, with a mean clinical follow-up time of 40 months. These authors observed a rate of reversal to the sinus rhythm that varied from 72% to 87%.

In a metanalysis study performed by Khargi et al. [13] the results of the surgical ablation using several energy sources including radiofrequency were compared with the traditional "Cox-Maze" III technique. Among the cases of ablation, the success rate was from 78.3% and with the conventional technique it was from 84.9% (p=0.03). The more favorable results found in the patients who were submitted to the traditional "Cox-Maze" III technique were justified by the greater percentage of patients with paroxysmal and isolated AF included in this group.

In Brazil, in the Instituto do Coração (InCor) of the Hospital das Clínicas, the Medical School of the University of São Paulo (HC-FMUSP), a study involving 70 patients with permanent atrial fibrillation and rheumatic mitral valve disease was performed [14]. The patients were divided into two groups, the Treated Group was composed of 42 patients who underwent radiofrequency ablation of AF and mitral valve surgery and the Control Group consisted of 28 patients who underwent mitral valve surgery in isolation.

In the Treated Group, radiofrequency ablation, with cardiopulmonary bypass, was mainly performed in the atrial endocardium. The mean times necessary for the application of the radiofrequency to the right and left atria were 8.2 and 14.1 minutes, respectively. After a mean follow up of 13.8 ± 3.4 months for the Treated Group and 11.5 ± 7.3 months for the Control Group, the cumulative rates of reversal to sinus rhythm were 79.4% and 26.9%, respectively ($p<0.05$).

Figure 3 illustrates the unipolar endocardial radiofrequency ablation apparatus being utilized in the endocardium of the left atrium proceeding to the isolation of the pulmonary veins.

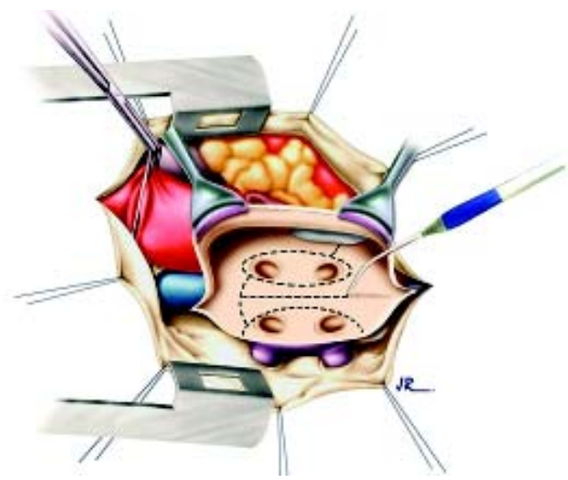

Fig. 3 - Unipolar apparatus with a tip irrigated with saline solution used to apply endocardial radiofrequency in the left atrium to isolate the pulmonary veins

Epicardial ablation

The possibility of epicardial ablation has the advantage of enabling the procedure to be performed in association with surgeries without the use of cardiopulmonary bypass, for example, during coronary arterial bypass grafting, highlighting the importance of this procedure due to a high prevalence of from 15% to 40% of this arrhythmia among patients who are submitted to this type of surgery [15].

The currently available apparatus of epicardial ablation is in the form of bipolar clamps. Electrodes are placed in the arms of the clamps through which the energy is transmitted.

Benussi et al. [16] performed epicardial radiofrequency ablation in associated with mitral valve surgery in 40 patients. After a mean clinical follow-up of 11.6 ± 4.7 months, 76.9% of the patients presented with sinus rhythm.

Gillinov and McCarthy [17] reported clinical experience using the "Atricure" bipolar apparatus for AF ablation in 120 patients who were submitted to associated heart surgeries. In 10 patients, blocking of the electrical impulses near to the pulmonary vein orifices was tested. In all patients this objective was achieved.

3. Microwaves

The apparatus used to apply microwaves can be rigid or flexible and the application can also be achieved in the epicardium or in the atrial endocardium.

The use of the microwaves for permanent AF ablation presents success rates of approximately 80% [18]. The method has some advantages including a short time of application, a high capacity to create transmural tissue lesions, a reduced risk of thromboembolic complications and the technique is easy to employ through minimally invasive techniques due to the high flexibility of the apparatus [19].

Endocardial ablation

Schuetz et al. [20] performed a study of 43 patients with permanent AF. The patients were randomized into two groups. In the first group of 24 patients, the Treated Group, ablation by microwaves was performed in the left atrium together with amputation of the left auricle. In the second group of 19 patients, the Control Group, only valve or coronary surgeries were performed. After 12 months of postoperative follow-up, 80% of the patients of the Treated Group and 33.3% of the patients of Control Group presented with sinus rhythm (p=0.036).

Epicardial ablation

Maessen et al. [21] performed microwave ablation in 24 patients who were submitted to heart surgeries. The surgical technique consisted in the amputation of the left auricle and microwave epicardial ablation around the pulmonary vein orifices. After a clinical follow-up of up to 9 months, 86.9% of the patients presented with sinus rhythm.

4. Ultrasound

The use of ultrasound as an energy source to create transmural lesions and AF ablation is recent with the initial experience more directed to its application through percutaneous catheters and for the treatment of paroxysmal AF [22].

Brick et al. [23] performed intraoperative ablation to treat permanent AF. Twenty-seven patients were submitted to ablation associated with other surgical procedures. The ablation lines followed the “Cox-Maze” III technique. At the moment of hospital discharge, the rate of reversal to sinus rhythm was 81.4%.

5. Laser rays

The utilization of laser in the treatment of AF is recent with, until now, only experimental studies. Fried et al. [24] conducted an experimental study using the Nd:YAG LASER system through optical fibers. The authors reported transmural lesions without evidence of tissue perforation or of lesions of adjacent structures. Thus they suggested that laser can be an alternative energy source to achieve the “Cox-Maze” III procedure.

6. Left atrial isolation

The isolation of electric impulses of the posterior region of the left atrium, which includes the pulmonary vein orifices, is closely linked to the physiopathology of AF [3]. Several authors recommend the isolation of the left atrium by ablation using different energy sources. Recently published reports related to the use of this technique present satisfactory rates of reversal to sinus rhythm.

Mohr et al. [25] performed radiofrequency ablation only in the left atrium associated with other surgical procedures in 243 patients. After a follow-up of up to 20 months, 72.5% of the patients remained in sinus rhythm.

In spite of the satisfactory outcomes observed by some authors with ablation only in the left atrium, permanent AF electrophysiological bases indicate the necessity of performing surgical procedures involving both atria. With this, the importance of lesions in the right atrium to prevent atrial flutter episodes after surgery is stressed.

7. Surgical treatment of atrial fibrillation by minimally invasive techniques.

Technological advances propitiated the development of minimally invasive techniques in the surgical treatment of AF. Saltman et al. [26] reported the case of a 74-year-old patient with AF who successfully underwent isolation of the pulmonary veins, by microwave ablation performed using videothoracoscopy.

Radiofrequency epicardial ablation around the pulmonary veins can also be performed using videothoracoscopy. A long and flexible probe is introduced into the thorax through special trocaters. The probe is positioned near the pulmonary veins, so that, on turning on of the apparatus, radiofrequency energy is released, causing a transmural lesion around the pulmonary veins.

End considerations and future perspectives.

The outcomes of the surgical treatment of AF must be considered over the long-term as in the first 3 to 6 months after the surgery the incidence of relapse of arrhythmia is high, without signifying an error in the procedure. It is acceptable that up to 40% of patients who undergo the “Cox-Maze” or some variant of this surgery, present AF

episodes in the postoperative period [27]. Maintenance using oral antiarrhythmic and anticoagulant medications in this period is recommended.

On analyzing the outcomes of the surgical treatment of AF, apart from reversal to sinus rhythm, it is fundamental to evaluate the rate of reestablishment of atrial contractility among patients who remain in sinus rhythm. The presence of effective atrial contractility is important to prevent the development of thromboembolic phenomena and is related with the hemodynamic performance, because it can contribute to up to 30% of the heart output [28].

According to different authors, the function of atrial transport can be reestablished in from 70% to 100% of patients after the "Cox-Maze" procedure using the conventional technique or with ablation, for example, by radiofrequency [2,5]. In the study developed in InCor – HCFMUSP using radiofrequency in patients with rheumatic mitral valve disease, we observed atrial contractility return rates in 90.3% of the patients maintained in sinus rhythm [14].

There are complications related to the techniques currently available for the surgical treatment of AF, two of which deserve mentioning: atrio-esophageal fistula and coronary artery injuries. Atrio-esophageal fistulae occur due to a perforation of the base of the left atrium close to the anterior wall of the esophagus. This complication, although rare, has been described by some authors [25,29]. In a study of 234 patients treated by radiofrequency ablation for AF with associated procedures, Mohr et al. [25] reported the occurrence of this complication in 3 (1.3%) patients, who needed surgical repair. In one of the patients, air embolization occurred causing a stroke, which evolved to the death of this patient. Gillnov et al. [30] described esophageal lesions during surgical ablation for AF in the base of the left atrium, which also caused the death of the patient.

There are surgical maneuvers that can be performed to reduce the risk of this complication, such as placing a compress in the posterior pericardial sack, to isolate the esophagus from the inferior section of the left atrium. In cases where transesophageal echocardiography is being utilized, the procedure must be cranially traced using the transducer during ablation in the inferior section of the left atrium.

Manasse et al. [31] reported a case of acute myocardial infarction, with a coronary cineangiography revealing a critical lesion in the left coronary artery trunk 3 months after microwave epicardial ablation associated with mitral valve surgery. The patient was submitted to coronary artery bypass grafting and presented with a satisfactory evolution. The authors attributed the occurrence of the left coronary artery lesion to bad positioning of the apparatus utilized for microwave ablation.

Fayad et al. [32] described stenosis of the circumflex artery after surgical ablation by radiofrequency. The authors reported the case of a patient who evolved with clinical angina pectoris and acute pulmonary edema, one year after AF ablation by radiofrequency. A coronary cineangiography revealed the presence of stenosis of the circumflex artery, adjacent to the site of the application of the radiofrequency energy. The stenosis was successful opened by coronary transluminal angioplasty.

The alternatives available today utilizing different energy sources to achieve the modified "Cox-Maze" III surgery present satisfactory results, with success rates of around 80%. These procedures are important as they allow the return to sinus rhythm through less invasive and rapidly performed techniques.

The future perspectives for the surgical treatment of AF will attempt to form a procedure considered ideal. This must present several characteristics including the creation of only the essential atrial lesions, using some currently available energy source to create the transmural lesions, which can be applied both to the endocardium and the atrial epicardium, can be performed without using cardiopulmonary bypass, and can be achieved through minimally invasive techniques, including with the utilization of thoracoscopy and robotics. The procedure should be effective in the treatment of several clinical forms of AF and atrial flutter [33].

Thus, the indication of surgical treatment for AF can be made earlier, involving the cases of isolated AF, that is, cases not associated with structural heart diseases and will be able to treat a greater number of patients with arrhythmias unresponsive to the clinical treatment.

BIBLIOGRAPHIC REFERENCES

1. Gillinov AM, Blackstone EH, McCarthy PM. Atrial fibrillation: current surgical options and their assessment. Ann Thorac Surg. 2002;74(6):2210-7.

2. Sie HT, Beukema WP, Misier AR, Elvan A, Ennema JJ, Haalebos MM et al. Radiofrequency modified maze in patients with atrial fibrillation undergoing concomitant cardiac surgery. J Thorac Cardiovasc Surg. 2001;122(2):249-56.

3. Cox JL. Atrial fibrillation I: a new classification system. J Thorac Cardiovasc Surg. 2003;126(6):1686-92.

4. Fuster V, Ryden LE, Asinger RW, Cannom DS, Crijns HJ, Frye RL et al. ACC/AHA/ESC guidelines for the management of patients with atrial fibrillation: Executive Summary. A report of the American College of Cardiology / American Heart Association Task Force on Practice Guidelines and the European Society of Cardiology Committee for Practice Guidelines and Policy Conferences (Committee to Develop Guidelines for the Management of Patients with Atrial Fibrillation). Circulation. 2001;104(17):2118-50.

5. Deneke T, Khargi K, Grewe PH, Laczkovics A, von Dryander S, Lawo T et al. Efficacy of an additional MAZE procedure using cooled-tip radiofrequency ablation in patients with chronic atrial fibrillation and mitral valve disease: a randomized, prospective trial. Eur Heart J. 2002;23(7):558-66.

6. Cox JL, Schuessler RB, D'Agostino HJ, Stone CM, Chang BC, Cain ME et al. The surgical treatment of atrial fibrillation III. Development of a definitive surgical procedure. J Thorac Cardiovasc Surg. 1991;101(4):569-83.

7. Cox JL, Jaquiss RD, Schuessler RB, Boineau JP. Modification of the maze procedure for atrial flutter and atrial fibrillation II. Surgical technique of the maze III procedure. J Thorac Cardiovasc Surg. 1995;110(2):485-95.

8. Nakagawa H, Lazzara R, Khastgir T, Beckman KJ, McClelland JH, Imai S et al. Role of the tricuspid annulus and the Eustachian valve/ ridge on atrial flutter: relevance to catheter ablation of the septal isthmus and a new technique for rapid identification of ablation success. Circulation. 1996;94(3):407-24.

9. Cox JL. The minimally invasive maze procedure. In: Franco KL, Verrier ED, editors. Advanced therapy in cardiac surgery. 2nd ed. 2003.

10. Sueda T, Nagata H, Orihashi K, Morita S, Okada K, Sueshiro M et al. Efficacy of a simple left atrial procedure for chronic atrial fibrillation in mitral valve operations. Ann Thorac Surg. 1997;63(4):1070-5.

11. Gaita F, Riccardi R, Calò L, Scaglione M, Garberoglio L, Antolini R et al. Atrial mapping and radiofrequency catheter ablation in patients with idiopathic atrial fibrillation. Electrophysiological findings and ablation results. Circulation. 1998;97(21):2136-45.

12. Sie HT, Beukema WP, Elvan A, Misier AR. Long-term results of irrigated radiofrequency modified maze procedure in 200 patients with concomitant cardiac surgery: six years experience. Ann Thorac Surg. 2004;77(2):512-7.

13. Karghi K, Hutten BA, Lemke B, Deneke T. Surgical treatment of atrial fibrillation: a systematic review. Eur J Cardiothorac Surg. 2005;27(2):258-65.

14. Abreu Filho CAC, Lisboa LAF, Dallan LA, et al. Efficacy of the maze procedure using cooled-tip radiofrequency ablation in patients with permanent atrial fibrillation and rheumatic mitral valve disease. Circulation. 2005, "in press".

15. Melo J, Voigt P, Sonmez B, Ferreira M, Abecasis M, Rebocho M et al. Ventral cardiac denervation reduces the incidence of atrial fibrillation after coronary artery bypass grafting. J Thorac Cardiovasc Surg. 2004;127(2):511-6.

16. Benussi S, Pappone C, Nascimbene S, Oreto G, Caldarola A, Stefano PL et al. A simple way to treat chronic atrial fibrillation during mitral valve surgery: the epicardial radiofrequency approach. Eur J Cardiothorac Surg. 2000;17(5):524-9.

17. Gillinov AM, McCarthy PM. Atricure bipolar radiofrequency clamp for intraoperative ablation of atrial fibrillation. Ann Thorac Surg. 2002;74(6):2165-8.

18. Gillinov AM, Smedira NG, Cosgrove III DM. Microwave ablation of atrial fibrillation during mitral valve operations. Ann Thorac Surg. 2002;74(4):1259-61.

19. Kress DC. Radiofrequency and microwave ablation for atrial fibrillation. In: Franco KL, Verrier ED, editors. Advanced therapy in cardiac surgery. 2nd ed. 2003.

20. Schuetz A, Schulze CJ, Sarvanakis KK, Mair H, Plazer H, Kilger E et al. Surgical treatment of permanent atrial fibrillation using microwave energy ablation: a prospective randomized clinical trial. Eur J Cardiothorac Surg. 2003;24(4):475-80.

21. Maessen JG, Nijs JF, Smeets JL, Vainer J, Mochtar B. Beating-heart surgical treatment of atrial fibrillation with microwave ablation. Ann Thorac Surg. 2002;74(4):S1307-11.

22. Wang JA, Sun Y, He H. Ultrasound ablation of pulmonary veins for treatment of paroxysmal atrial fibrillation. J Zhejiang Univ Sci. 2003;4(6):745-8.

23. .Brick AV, Seixas T, Portilho C, Peres AK, Vieira Jr JJ, Melo Neto R et al. Tratamento intra-operatório da fibrilação atrial crônica com ultra-som. Rev Bras Cir Cardiovasc. 2001;16(4):337-49.

24. Fried NM, Lardo AC, Berger RD, Calkins H, Halperin HR. Linear lesions in myocardium created by Nd:YAG laser using diffusing optical fibers: in vitro and in vivo results. Lasers Surg Med. 2000;27(4):295-304.

25. Mohr FW, Fabricius AM, Falk V, Autschbach R, Doll N, Von Oppell U et al. Curative treatment of atrial fibrillation with intraoperative radiofrequency ablation: short-term and midterm results. J Thorac Cardiovasc Surg. 2002;123(5):919-27.

26. Saltman AE, Rosenthal LS, Francalancia NA, Lahey SJ. A completely endoscopic approach to microwave ablation for atrial fibrillation. Heart Surg Forum. 2003;6(3):E38-41.

27. Ad N, Cox JL. Combined mitral valve surgery and the Maze III procedure. Semin Thorac Cardiovasc Surg. 2002;14(3):206-9.

28. Van Wagoner DR. Basic mechanisms of atrial fibrillation. Cleve Clin J Med. 2003;70(suppl. 3):S2-5.

29. Sonmez B, Demirsoy E, Yagan N, Unal M, Arbatli H, Sener D et al. A fatal complication due to radiofrequency ablation for atrial fibrillation: atrio-esophageal fistula. Ann Thorac Surg. 2003;76(1):281-3.

30. Gillinov AM, Pettersson G, Rice TW. Esophageal injury during radiofrequency ablation for atrial fibrillation. J Thorac Cardiovasc Surg. 2001;122(6):1239-40.

31. Manasse E, Medici D, Ghiselli S, Ornaghi D, Gallotti R. Left main coronary arterial lesion after microwave epicardial ablation. Ann Thorac Surg. 2003;76(1):276-7.

32. Fayad G, Modine T, Le Tourneau T, Decoene C, Azzaoui R, Al-Ruzzeh S et al. Circumflex artery stenosis induced by intraoperative radiofrequency ablation. Ann Thorac Surg. 2003;76(4):1291-3.

33. Cox JL. Atrial fibrillation II: Rationale for surgical treatment. J Thorac Cardiovasc Surg. 2003;126(6):1693-9.